



PATIENT

Bandido Marrufo

SPECIES

Canine

BREED

Aussie Mix

SEX

M

AGE

2

WEIGHT

45

INTERPRETED BY

R. McKenzie Daniel,
DVM, DABVP
(Canine and Feline)

IMAGING PERFORMED BY

Jenn

HOSPITAL NAME

Rockaway Animal
Hospital

REFERRING VET

Dr Maniar

INVOICE

23608

DATE

01/19/2026

PRESENTING CLINICAL SIGNS

V/D decreased appetite ate goose feces , gastroenteritis , suspect dietary indiscretion

ULTRASONOGRAPHIC EXAMINATION OF THE ABDOMEN

Urinary System

The urinary bladder, trigone, cystourethral junction, and visible pelvic urethra exhibited normal thickness and tone. Anechoic urine was present in the lumen with no evidence of urine/lumen sediment, mineral, or calculi. The ureteral papillae were normal. The ureters were not visible, which is normal. No evidence of inflammatory or neoplastic changes was noted.

Normal size and margination were present in the kidneys. A normal 1:3 cortex / medulla ratio and normal corticomedullary definition were maintained. The echogenicity of the cortex was similar to or slightly less than normal liver parenchyma while the medulla echogenicity was hypoechoic to the cortex with no evidence of pelvic dilation. The left kidney measured 6.0 cm in length. The right kidney measured 5.5 cm in length.

The area of the aortic trifurcation was free of pathology.

The prostate gland appeared normal and free of pathology

Adrenal Glands

The bilateral adrenal glands were overtly normal in size, position and shape. The left adrenal gland measured 0.45 cm width at the caudal pole The right adrenal gland measured 0.49 cm width at the caudal pole.

Spleen

The spleen exhibited a finely textured and homogenous parenchyma which was hyperechoic to the liver and renal cortical parenchyma. The capsule was smooth and regular without apparent expansion. The splenic vasculature at the hilus was normal in volume with no evidence of congestion or thrombosis. Acute to chronic inflammatory, neoplastic, or benign parenchyma changes were not noted.

Liver/Gallbladder

The liver was subjectively normal in size, structure, and contour. The liver parenchyma was uniform and hypoechoic to the spleen with a mild coarse echotexture. Normal vascular volume. The hepatic and portal vasculature were normal in appearance without signs of congestion. The gallbladder was non-distended in size with thin walls and primarily anechoic luminal content. The cystic and common bile ducts were normal.

Gastrointestinal

The stomach presented intact wall layering with a normal wall layer ratio. The lumen of the stomach was empty with no signs of ileus, obstruction or foreign material.

The small intestine presented intact wall layering with 1:3 muscularis/mucosa ratio. The lumen of the small intestine was empty with no signs of mechanical/metabolic ileus, obstruction or foreign material.



PATIENT

Bandido Marrufo

SPECIES

Canine

BREED

Aussie Mix

SEX

M

AGE

2

WEIGHT

45

Normal visible colon wall layers were present. Empty segmental colon with segmental semi-formed to soft fecal matter and lumen gas.

Pancreas

The parenchyma of the left limb, body and right limb of the pancreas presented isoechoic to the adjacent omental fat. A normal curvilinear capsule contour of the pancreas was present. The visible pancreatic duct was normal. No signs of active inflammation or neoplastic disease was evident.

Free Abdomen

No omental masses, overt lymphadenopathy or peritoneal effusion was present.

ULTRASONOGRAPHIC FINDINGS

Primary

- Overall, sonographically unremarkable gastrointestinal tract /colon- no evidence of foreign material or obstructive pattern with semi-formed to soft fecal matter in colon.

INTERPRETATION OF THE FINDINGS & FURTHER RECOMMENDATIONS

Gastrointestinal support and empirical therapy for nonspecific gastroenteritis recommended. Dietary indiscretion, infectious disease, enterotoxin, non-structural inflammatory bowel, occult parasitism, occult Addison's disease, low-grade pancreatitis are all potentials.

INTERPRETED BY

R. McKenzie Daniel,
DVM, DABVP
(Canine and Feline)

IMAGING PERFORMED BY

Jenn

HOSPITAL NAME

Rockaway Animal
Hospital

REFERRING VET

Dr Maniar

INVOICE

23608

DATE

01/19/2026



PATIENT

Bandido Marrufo

SPECIES

Canine

BREED

Aussie Mix

SEX

M

AGE

2

WEIGHT

45

INTERPRETED BY

R. McKenzie Daniel,
DVM, DABVP
(Canine and Feline)

IMAGING PERFORMED BY

Jenn

HOSPITAL NAME

Rockaway Animal
Hospital

REFERRING VET

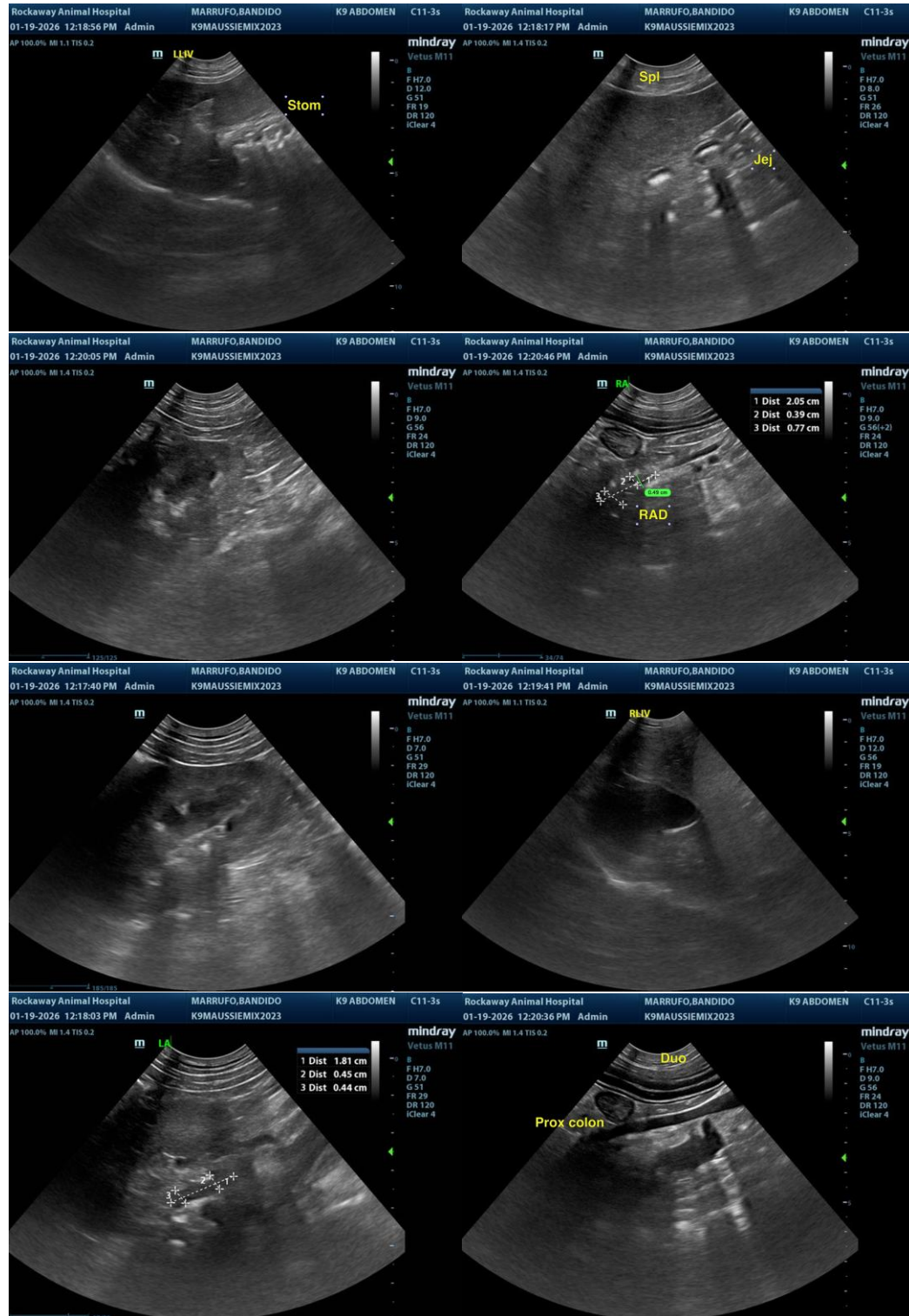
Dr Maniar

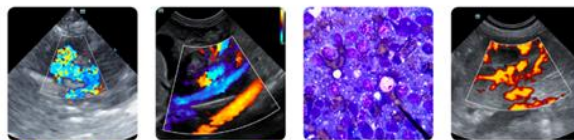
INVOICE

23608

DATE

01/19/2026





PATIENT

Bandido Marrufo

The information and recommendations provided are based on the images presented by the referring veterinarian/sonographer. No evaluation can be communicated regarding pathology that was not visible in the image/video clips provided.

SPECIES

Canine

Thank you for this referral. If the clinical or image interpretation does not parallel your findings or if I can be of any further assistance, please contact me.

BREED

Aussie Mix

R. McKenzie Daniel, DVM, DABVP (Canine/Feline Practice)

info@sonopath.com

SEX

M

AGE

2

WEIGHT

45

INTERPRETED BY

R. McKenzie Daniel,
DVM, DABVP
(Canine and Feline)

IMAGING PERFORMED BY

Jenn

HOSPITAL NAME

Rockaway Animal
Hospital

REFERRING VET

Dr Maniar

INVOICE

23608

DATE

01/19/2026